Laparoscopic management of adnexal masses: a gold standard?

Michel Canis, Benoit Rabischong, Celine Houlle, Revaz Botchorishvili, Kris Jardon, Antoine Safi, Arnaud Wattiez, Gérard Mage, Jean Luc Pouly and Maurice Antoine Bruhat

Purpose of review

To review recent literature on the laparoscopic management of adnexal masses, when this approach may be considered as a gold standard.

Recent findings

Cyst rupture was recently demonstrated to be a significant prognostic factor in stage I invasive epithelial carcinoma, and it was recommended to restrict the laparoscopic approach to patients with preoperative evidence that the cyst was benign. The laparoscopic approach is still highly controversial in masses suspicious at ultrasound. The limits of the laparoscopic approach are discussed reviewing recent literature and our experience. The laparoscopic management of adnexal masses appears to be safe in most hospitals even in developing countries. This approach is being used with increasing frequency in unusual indications such as newborns, children, adolescents and pregnant women. The learning curve for endoscopic surgery appears to be longer than expected. Many patients with benign adnexal masses, such as ovarian endometrioma, are still treated by laparotomy or with an inadequate endoscopic technique. Several studies have suggested that the stripping technique is a tissue-sparing procedure.

Summary

The laparoscopic puncture of malignant ovarian tumours confined to the ovaries is uncommon, and should be avoided whenever possible. The teaching of endoscopy is essential to promote adequate procedures performed according to the principles of microsurgery and to preserve postoperative ovarian physiology.

Keywords

Laparoscopy, ovarian cancer, dissemination, pediatric surgery, cystectomy, ovocyte, ovulation

Curr Opin Obstet Gynecol 14:423–428. © 2002 Lippincott Williams & Wilkins.

Department of Obstetrics, Gynecology and Reproductive Medicine, CHU Polyclinique, Boulevard Léon Malfreyt, 63033 Clermont-Ferrand, France

Correspondence to Michel Canis, Department of Obstetrics, Gynecology and Reproductive Medicine; CHU Polyclinique, Boulevard Léon Malfreyt, 63033 Clermont-Ferrand, France
Tel: +33 4 73 31 60 53; fax: +33 4 73 93 17 06; e-mail: mcanis@chu-clermontferrand.fr

Current Opinion in Obstetrics and Gynecology 2002, 14:423–428

© 2002 Lippincott Williams & Wilkins
1040-872X

Introduction

Laparoscopic surgery could be considered to be the gold standard in the management of adnexal masses. Its value has been demonstrated in prospective randomized studies [1,2]. In contrast, recent literature suggests that this issue remains highly controversial [3••,4•,5], that benign ovarian neoplasms, such as ovarian endometrioma, are still treated by laparotomy by many gynaecologists, and that the endoscopic techniques used by others are inadequate [6,7•]. On the other hand, the laparoscopic approach has been further evaluated in new or uncommon indications [8•,9–10].

Laparoscopy, puncture and the risks of cancer dissemination: can we end this debate?

In January 2001, Vergote *et al.* [3••] re-emphasized the prognostic importance of surgical rupture; 1545 patients with stage I epithelial ovarian carcinoma from six pre-existing databases were included and their records retrospectively reviewed. Disease-free survival was used to establish the prognostic value. The degree of differentiation, rupture before or during surgery, Federation of Gynaecology and Obstetrics stage, and age were found to be independent and strong prognostic factors, both at univariate and multivariate analysis (Table 1). Several criticisms can be addressed at this very important study. First, the analysis was retrospective. Second, peritoneal washings and scraping of the diaphragm was not routinely performed in five of the six centres included. Third, lymph node evaluation was only a sampling of palpable nodes not a routine para-aortic and pelvic lymphadenectomy. Fourth, it was not possible to distinguish between surgical rupture and ovarian puncture. Fifth, patients whose tumours had adhesions to adjacent organs were included or excluded depending on the absence or presence of an invasion of the adjacent structures. This distinction is probably

Table 1. Five year disease-free survival rate in relation to rupture of the tumour

Rupture	Number with characteristics	5 year disease-free survival in % (SE)
No	859 (56%)	83.3 (1.4)
Before surgery	122 (8%)	70.2 (4.6)
During surgery	89 (6%)	71.6 (4.8)
Unknown	475 (31%)	75.4 (5.4)

Modified from Vergote *et al.* [3••], with permission.

difficult to assess retrospectively as the adjacent structures may not have been routinely biopsied. Despite these criticisms, the study suggested that opening of the cyst is or may be a significant prognostic factor and should be avoided whenever possible [11•]. However, these data do not demonstrate that laparoscopic puncture is a significant prognostic factor, particularly when minimizing spillage and its consequences by using an adequate technique with a strong aspiration system and meticulous peritoneal lavage.

To emphasize the importance of this question, a very rare complication was recently reported in a 37-year-old patient operated for a teratoma [4•]. The cyst was diagnosed at ultrasound and at laparoscopy as a benign teratoma, the contents were difficult to aspirate, spillage occurred and was treated with copious irrigation. The cystic mass was removed without technical difficulties. Microscopic examination showed foci of moderately differentiated infiltrating squamous cell carcinoma. At re-operation, 33 days after the first procedure, metastases were found in nodules removed from the peritoneum of the anterior abdominal wall and of the posterior cul-de-sac. The tumour was classified as a stage IIc squamous cell carcinoma, and the patient received postoperative chemotherapy and radiotherapy. This complication is rare, but the diagnosis of a squamous cell carcinoma arising in a small teratoma is probably very difficult. When the tumour is small, the ultrasonographic appearance is similar to that of benign teratomas, CA 125 is not increased in squamous cell tumours, and finally macroscopic inspection of the internal aspect of a teratoma is difficult because of the sebaceous cyst content. A possible sign of malignancy would be a difficult cleavage of the cyst wall at the site of invasion. This may have occurred in this case, because foci of atypical keratinocytes, consistent with the diagnosis of squamous cell carcinoma, were found inside the ovary at re-operation. At laparotomy, the diagnosis would also be very difficult, and similar complications may occur. In 1986, Helawa *et al.* [12] reported that early ovarian cancers might be missed at laparotomy, and that 20% of patients are upstaged after an inadequate management by laparotomy. The problem is rather the accuracy of the surgical diagnosis rather than the method of access to the abdomen. As most adnexal masses are either obviously benign or obviously malignant, gynaecologists may forget that the diagnosis of malignancy may be difficult. Recently, Hopkins *et al.* [5] reported three more cases of dissemination after inadequate laparoscopic management. That paper included too few surgical data to understand these complications. However, the procedures, probably inadequate, included morcellation of an ovary, wedge biopsy without cystectomy and the rupture of a bag.

These papers again raised very important issues. First, every case should be managed very carefully because rare tumours may be encountered leading to postoperative complications. Second, as discussed below, the technique of cystectomy should be meticulous to prevent tears of the cyst wall and incomplete cystectomies. Third, the puncture of stage I ovarian cancer may have potential risks and should be avoided whenever possible. This problem is also encountered in young patients managed by laparotomy for large masses, because surgeons tend to reduce the size of their incision and to puncture the mass [13•]. Recently, Shozu *et al.* [13•] proposed a technique to achieve leak-proof puncture through a mini-laparotomy using a plastic bag and cyanoacrylate adhesive. Similar reliable devices are not available for laparoscopy. Until they are, the risks must be reduced as much as possible.

An accurate preoperative pathological diagnosis is the best approach, allowing the patient to be referred to an oncological surgeon, and the decision to be made to use a laparotomy only when necessary. Unfortunately, Mol *et al.* [14], when retrospectively evaluating 21 prognostic models proposed to distinguish benign from malignant adnexal masses, showed that the diagnostic performance of any model is much lower when used by other investigators. The authors found that to obtain a strict preoperative selection with a very high sensitivity, the specificities ranged between 0.45 and 0.60.

A meticulous preoperative evaluation is recommended, but realistic clinical management cannot be based on the results of experts, because experts cannot examine all patients. Vergote *et al.* [3••] stated that 'Laparoscopy should be restricted to patients with preoperative evidence that the cyst is benign'. The problem is to define the evidence. Excluding entirely cystic and selected septated masses (less than three septa or septa of less than 3 mm) among 230 adnexal masses suspicious at ultrasound operated in our department, only 37 (18.9%) were malignant or low malignant potential tumours [15]. We calculated that if a laparotomy was performed for every adnexal mass suspicious at ultrasound, approximately 40% of patients treated for a benign mass would be managed by laparotomy (Table 2). Therefore, we and probably most departments do not use such a strict preoperative selection. In a group of 1600 patients managed by laparoscopy, 32 invasive cancers and 34 low malignant potential tumours were encountered. Only 16 of the invasive tumours were stage I; among these cases four stage Ia were punctured before the surgical diagnosis of suspicious or malignant tumours [11•]. In that study, only 61% of patients were operated for a mass that was preoperatively considered to be obviously benign. The risk of puncture of a stage Ia tumour is fairly low. Most ovarian cancers are suspected

Table 2. Calculated incidence of laparotomy

Data used to calculate incidence of laparotomy	Total
Total number of patients	549
Patients managed by laparotomy	18
Patients managed by laparoscopy	531
Masses suspicious at ultrasound	201
Cancer and borderline tumours	28
Benign masses suspicious at surgery	59
Benign masses non-suspicious at surgery	429
Laparotomies for technical difficulties	10
Results – all patients	
N and rate of laparotomy[a], if it was indicated for:	
All benign masses suspicious at ultrasound	233 (45.2%)
All benign masses suspicious at surgery	115 (20.9%)
True incidence in our department during study[b]	50 (9.1%)
Patients operated for benign masses only	
N and rate of laparotomy[a], if it was indicated for:	
All benign masses suspicious at ultrasound	205 (42.0%)
All benign masses suspicious at surgery	69 (14.1%)

These theoretical incidences of laparotomies were calculated using data obtained in 549 patients managed in our department over a 3-year period. [a]All these results included all the malignant tumours (cancer, borderline) and all the laparotomies performed for technical reasons. [b]Including all the restaging procedures and the laparotomies required for the treatment of cancer patients.

without puncture as a result of extracystic signs of malignancy. Similarly a highly suspicious ultrasonographic appearance makes puncture unnecessary when the ovarian origin of the mass has been confirmed at laparoscopy.

We proposed cautious management [11•]. First, the preoperative evaluation should be meticulous, because it is the first step in the surgical intracystic examination. In suspicious masses, magnetic resonance imaging appears to be very interesting [16]. Non-suspicious adnexal masses may be operated by laparoscopy in any department, whereas suspicious masses should be operated by laparoscopy in departments in which a gynaecological oncologist and frozen sections are always available. At laparoscopy, after peritoneal cytology and a thorough examination of the ovaries and the peritoneum, the puncture will be decided cautiously according to intra- and preoperative data. If the mass is diagnosed as suspicious at surgery, then it should be treated by laparotomy [11•]. There is an ongoing debate among laparoscopists as to whether laparotomy should be performed before or after the results of frozen sections [11•,17]. We showed that performing a laparotomy for all masses suspicious at surgery before the results of frozen sections would lead to a reasonable rate of laparotomy, and may be proposed as a safe limit for laparoscopy [11•] (Table 2).

Another alternative to avoid puncture would be to perform a routine adnexectomy for all adnexal masses suspicious at ultrasound. However, this management would result in a high incidence of adnexectomy in young patients. In patients less than 40 years old, adnexectomy should be performed only in masses suspicious at surgery; it should not be decided before the surgical procedure because of a suspicious ultrasonographic appearance [11•].

The debate will end when a reliable preoperative diagnosis based on imaging techniques and tumour markers becomes available. Until then, as stated by Vergote *et al.* [3••], 'rupture or puncture of malignant ovarian tumour confined to the ovaries should be avoided whenever possible'. The literature suggests that the risks are related to inadequate surgical diagnoses, and are not higher at laparoscopy than at laparotomy [11•,12]. Techniques that prevent or decrease the incidence and the consequences of spillage, similar to that recently reported for mini-laparotomy, should be developed as soon as possible.

New or uncommon indications

Laparoscopic surgery is being used with increased frequency in the management of adnexal masses encountered in paediatrics and during pregnancy.

Paediatric surgery

Templeman *et al.* [8•] reported four cases of adnexal cyst managed by laparoscopy using microendoscopy instruments in babies less than 3 months old. Anaesthesia was carefully monitored, the intra-abdominal pressure maintained below 8 mmHg, and 3 mm ancillary ports were used. The procedures performed were a puncture, two cystectomies and one oophorectomy in a case of torsion. The postoperative course was uneventful. Esposito *et al.* [18], who operated 22 babies without intra- or postoperative complications, had reported a similar experience. The insufflation pressure should be maintained below 10 mmHg and even below 8 mmHg, humidified gas was recommended to prevent hypothermia [8•], and it seemed to be important to insert ancillary ports high enough on the abdomen (above the umbilicus) to provide sufficient space to operate. This very attractive approach requires further evaluation. It should be reserved for persistent cysts, as most fetal ovarian cysts are functional and will resolve spontaneously [8•,19].

Laparoscopy appears to be very promising in girls less than 15 years old, as most adnexal masses are benign [20]. However, this approach should be used cautiously in masses complex at ultrasound with clinical evidence of hormonal activity, which are often malignant [20].

Pregnancy

A review article [21] concluded that cumulative experience suggested that laparoscopic surgery might be performed safely in pregnant patients. Most of the adnexal masses discovered at ultrasound during the

first trimester of pregnancy are functional cysts and resolve spontaneously at the beginning of the second trimester. Masses that persist into the second trimester should be removed. Hess *et al.* [22] suggested that elective surgical treatment was less morbid than surgery for symptomatic masses in an emergency setting. Several papers confirmed that the laparoscopic management of adnexal masses during pregnancy is safe and effective [10,21,23,24]. This approach was questioned in 1996, when Amos *et al.* [25] reported four fetal deaths among seven pregnant patients operated by laparoscopy. Since then, most reports have confirmed that fetal death, preterm labour and spontaneous abortion after surgery are rare, not more common than after laparotomy [10,21,23,24]. Their management should be adapted. Persistent masses should be operated early during the second trimester to minimize the difficulties related to the uterine volume. To create the carbon dioxide pneumoperitoneum, we generally use a Veress needle inserted perpendicularly to the abdominal wall in the left hypochondrium; the umbilical trocar is inserted blindly towards the upper abdomen. An open technique is a safe alternative [10]. Ancillary trocars are inserted under direct visualization; their situations should be adapted to the size of the uterus. The manipulation of the uterus should be kept to a minimum or avoided completely. Generally the adnexal mass is found in the posterior cul-de-sac behind the uterus, and the most difficult step of the procedure is to lift the adnexal mass into the abdomen. To prevent damage to the adnexal vessels, this step is achieved by pulling slowly and gently on the ovarian ligaments with two atraumatic forceps. Thereafter, the surgical procedure is similar to that performed in non-pregnant patients.

The technique is used everywhere but the learning curve is long!

The laparoscopic management of adnexal masses is used safely in most hospitals even in developing countries [26–28]. Besides these encouraging results, recent papers have suggested that the learning curve is long. Kalegyn and Sadykova [6] proposed managing ovarian cyst 'using a marsupialization technique'. The cyst was punctured intraperitoneally and the ovary was brought outside the abdomen using a small laparotomy of 1.5–2.5 cm in length. The cystectomy is then performed outside the abdomen. It seems surprising to publish again details of a technique, used many years ago, when no reliable grasping forceps were available [29]. This approach may appear to be easier, but it increases the risk of abdominal contamination and is more traumatic for the ovary. Therefore, when the instruments required to achieve an intraperitoneal cystectomy are available, there is no rationale to using this approach. This technique would be acceptable only in departments where laparoscopic instruments are not available, or to manage very large teratomas with solid contents.

A recent anonymous survey performed in the UK [7•], on the laparoscopic treatment of ovarian endometrioma, surprisingly showed that 42.3% of consultants manage ovarian endometrioma by laparotomy. Among those who use a laparoscopic approach, 61% perform a fenestration, followed in most cases by an electrosurgical ablation. Many endometriomas are not effectively treated by laparoscopy, because electrosurgery is not a useful instrument in the treatment of ovarian endometrioma. Without preoperative medical treatment, it is difficult to identify the areas that should be ablated and the areas that have been effectively ablated, because the surgeon does not know how deep to go and how deep he is coagulating. When a laser is not available, cystectomy is the best surgical technique and is used by more than 90% of consultants who treat endometrioma by laparotomy.

Such studies demonstrated that the learning curve for laparoscopic surgery is longer than expected. Each surgeon has his own learning curve depending on his surgical experience and manual abilities. However, the teaching of new surgical procedures is probably not always adequate. Surgical techniques are often 'summarized' using one or two sentences and wonderful videotapes, to try and demonstrate that the technique is simple, easy and fast. Consequently, beginners who are not able to repeat the procedure may conclude that they are not gifted enough, or that they do not have the adequate instruments and they treat their patients by laparotomy. Surgeons trained in the management of adnexal masses for many years have developed many tricks that would help beginners, and should be reported and taught as often as possible.

Is the stripping technique a tissue-sparing procedure?

Three studies recently evaluated the consequences of laparoscopic cystectomy on ovarian function [30,31••,32]. Muzii *et al.* [31••] performed a pathological examination of specimens excised using a stripping technique, looking for the presence and the nature of ovarian tissue adjacent to the cyst wall. Ovarian tissue adjacent to the cyst wall was found in 15 out of the 42 cases, including 14 out of 26 specimens of ovarian endometrioma and one out of 16 specimens of non-endometriosis ovarian cyst. The ovarian tissue identified never showed the morphological characteristics observed in normal ovarian tissue. Secondary follicles were never observed, which according to the authors suggested that this tissue had no functional value and that the stripping technique is a tissue-sparing procedure [31••].

Most surgeons would have anticipated that cystectomy of non-endometriosis ovarian cyst is a tissue-sparing procedure because the dissection is easy and bloodless in most cases. In contrast, there is an ongoing debate on the best laparoscopic technique to manage ovarian endometrioma [7•]. We recently reported that at in-vitro fertilization embryo transfer, the number of ovocytes and embryos was not significantly decreased in patients who had previously undergone a cystectomy for an ovarian endometrioma when compared with patients treated for endometriosis without ovarian endometrioma or with patients with tubal infertility [30]. Maneschi *et al.* [34] also found that the ovarian tissue surrounding ovarian endometrioma showed morphological patterns similar to those of normal ovarian tissue in only 19% of cases, whereas the ovarian tissue surrounding benign ovarian neoplasms was normal in 80% of cases, suggesting that the functional value of the ovary is altered by the disease rather than by the surgical procedure. Recently, Hachisuga and Kawarabayashi [33] reported a histopathological analysis of laparoscopically treated ovarian endometriotic cysts. Among 73 endometriomas, fibrosis was found in 41, follicles in 42, and corpus albicans in 30. Surprisingly, the number of cyst walls showing follicles was much higher among 61 cysts easily stripped away (69%) than among 12 cysts stripped away with difficulty (0%). In that report, only primordial follicles were found; there were no primary or secondary follicles, again suggesting, according to the criteria used by Muzii *et al.* [32••], that the ovarian tissue removed around the cyst did not show the morphological characteristics observed in normal ovarian tissue. It is well known that the stripping of ovarian endometrioma may be more difficult, and the technique needs to be adapted. In a recent study [30], we described a nine-step procedure, the key point of which was that after an easy initial part of the dissection, the cleavage became more difficult when red fibrotic fibres were seen on the surface of the cyst (Fig. 1). In this situation, the classic stripping technique (pulling with more strength on both forceps) would remove the fibrosis around the cyst, damage the ovary, and induce bleeding and severe thermal damage. To avoid this complication, one should expose the plane with two grasping forceps, coagulate and cut the red fibres on the surface of the cyst to identify the cleavage plane close to the cyst wall (Figure 1). Thereafter, the plane is correct when the surface of the cyst wall is again white and dissection induces minimal bleeding.

The stripping technique can be considered to be a tissue-sparing procedure. However, it is not magic, the dissection may be difficult and it should be performed according to the principles of microsurgery [35]; the cyst wall should not be torn by too strong or too fast a traction on the grasping forceps. The cleavage plane should be visible during all of the procedure. To follow this rule, a careful haemostasis is necessary, and the grasping forceps should be moved often enough to ensure perfect exposure of the cleavage plane. Beginners often tend to avoid frequent movements of the grasping forceps and to prefer very long tractions. However, when grasping forceps are far from the cleavage plane, tractions are much less effective. Cystectomy should be almost bloodless. In the case of severe bleeding, the procedure should be stopped, haemostasis achieved, and the cause of the damage to the ovary identified and treated adequately. Difficulties are often the consequence of inadequate exposure, but may also be related to fibrosis in endometrioma and previously operated ovaries, or to suspicious areas in other ovarian neoplasms.

Figure 1. Dissection of an ovarian endometrioma

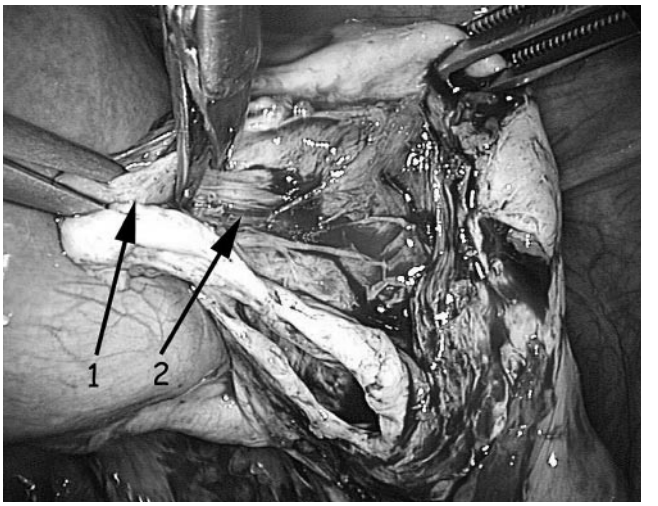

The cyst wall is grasped with the left forceps, the ovary with the right. (1) White area of the cyst wall, which was stripped easily. (2) Fibres (red or pink at surgery), visible on the cyst wall, are coagulated and cut to identify the cleavage plane close to the endometrioma.

References and recommended reading

Papers of particular interest, published within the annual period of review, have been highlighted as:
• of special interest
•• of outstanding interest

1 Mais V, Ajossa S, Piras B, *et al.* Treatment of nonendometriotic benign adnexal cysts: a randomized comparison of laparoscopy and laparotomy. Obstet Gynecol 1995; 86:770–774.

2 Yuen PM, Yu KM, Yip SK, *et al.* A randomized prospective study of laparoscopy and laparotomy in the management of benign ovarian masses. Am J Obstet Gynecol 1997; 177:109–114.

3 •• Vergote I, De Brabanter J, Fyles A, *et al.* Prognostic importance of degree of differentiation and cyst rupture in stage I invasive epithelial ovarian carcinoma. Lancet 2001; 357:176–182.
A very important retrospective study on the consequences of surgical rupture.

4 • Mayer C, Miller DM, Ehlen TG. Peritoneal implantation of squamous cell carcinoma following rupture of a dermoid cyst during laparoscopic removal. Gynecol Oncol 2002; 84:180–183.
A rare situation that emphasizes that the management of every patient should be very careful; simple cases are not all simple!

5 Hopkins MP, von Gruenigen V, Gaich S. Laparoscopic port site implantation with ovarian cancer. Am J Obstet Gynecol 2000; 182:735–736.

6 Kalegyn AV, Sadykova MH. Marsupialization of the cyst as a step in laparoscopic management of ovarian cysts. J Am Assoc Gynecol Laparosc 2001; 8:568–572.

7 • Jones KD, Fan A, Sutton CJ. The ovarian endometrioma: why is it so poorly managed?: indicators from an anonymous survey. Hum Reprod 2002; 17:845–849.

A surprising anonymous survey that demonstrates how long is the learning curve for new surgical procedures.

8 • Templeman CL, Reynolds AM, Hertweck SP, Nagaraj HS. Laparoscopic management of neonatal ovarian cysts. J Am Assoc Gynecol Laparosc 2000; 7:401–404.

A new indication for laparoscopic management of adnexal masses, which appears very attractive in pediatric surgery.

9 Eltabbakh GH, Kaiser JR. Laparoscopic management of a large ovarian cyst in an adolescent. A case report. J Reprod Med 2000; 45:231–234.

10 Moore RD, Smith WG. Laparoscopic management of adnexal masses in pregnant women. J Reprod Med 1999; 44:97–100.

11 • Canis M, Botchorishvili R, Manhes H, *et al.* Management of adnexal masses: role and risk of laparoscopy. Semin Surg Oncol 2000; 19:28–35.

A review of the literature and of our long experience in the management of adnexal masses, 1600 cases are discussed.

12 Helawa ME, Krepart GV, Lotocki R. Staging laparotomy in early epithelial ovarian carcinoma. Am J Obstet Gynecol 1986; 154:282–286.

13 • Shozu M, Segawa T, Sumitani H, Inoue M. Leak-proof puncture of ovarian cysts: instant mounting of plastic bag using cyanoacrylate adhesive. Obstet Gynecol 2001; 97:1007–1010.

Similar devices would be very interesting for laparoscopic surgeons.

14 Mol BW, Boll D, De Kanter M, *et al.* Distinguishing the benign and malignant adnexal mass: an external validation of prognostic models. Gynecol Oncol 2001; 80:162–167.

15 Canis M, Pouly JL, Wattiez A, *et al.* Laparoscopic management of adnexal masses suspicious at ultrasound. Obstet Gynecol 1997; 89:679–683.

16 Jeong YY, Outwater EK, Kang HK. Imaging evaluation of ovarian masses. Radiographics 2000; 20:1445–1470.

17 Pejovic T, Nezhat F. Laparoscopic management of adnexal masses: the opportunities and the risks. Ann NY Acad Sci 2001; 943:255–268.

18 Esposito C, Garipoli V, Di Matteo G, De Pasquale M. Laparoscopic management of ovarian cysts in newborns. Surg Endosc 1998; 12:1152–1154.

19 Dolgin SE. Ovarian masses in the newborn. Semin Pediatr Surg 2000; 9:121–127.

20 Templeman C, Fallat ME, Blinchevsky A, Hertweck SP. Noninflammatory ovarian masses in girls and young women. Obstet Gynecol 2000; 96:229–233.

21 Fatum M, Rojansky N. Laparoscopic surgery during pregnancy. Obstet Gynecol Surv 2001; 56:50–59.

22 Hess LW, Peaceman A, O'Brien WF, *et al.* Adnexal mass occurring with intrauterine pregnancy: report of fifty-four patients requiring laparotomy for definitive management. Am J Obstet Gynecol 1988; 158:1029–1034.

23 Soriano D, Yefet Y, Seidman DS, *et al.* Laparoscopy versus laparotomy in the management of adnexal masses during pregnancy. Fertil Steril 1999; 71:955–960.

24 Yuen PM, Chang AM. Laparoscopic management of adnexal mass during pregnancy. Acta Obstet Gynecol Scand 1997; 76:173–176.

25 Amos JD, Schorr SJ, Norman PF, *et al.* Laparoscopic surgery during pregnancy. Am J Surg 1996; 171:435–437.

26 Raiga J, Kasia JM, Bruhat MA. Laparoscopic surgery in the Cameroon. Int J Gynaecol Obstet 1999; 65:65–66.

27 Mendilcioglu I, Zorlu CG, Trak B, *et al.* Laparoscopic management of adnexal masses. Safety and effectiveness. J Reprod Med 2002; 47:36–40.

28 Lok IH, Sahota DS, Rogers MS, Yuen PM. Complications of laparoscopic surgery for benign ovarian cysts. J Am Assoc Gynecol Laparosc 2000; 7:529–534.

29 Mage G, Canis M, Manhes H, *et al.* Laparoscopic management of adnexal cystic masses. J Gynecol Surg 1990; 6:71–79.

30 Canis M, Candiani M, Giambelli F, *et al.* Laparoscopic management of ovarian teratoma. It J Obstet Gynecol 1997; 2:47–53.

31 •• Canis M, Pouly JL, Tamburro S, *et al.* Ovarian response during IVF-embryo transfer cycles after laparoscopic ovarian cystectomy for endometriotic cysts of >3 cm in diameter. Hum Reprod 2001; 16:2583–2586.

The ovarian response during in-vitro fertilization embryo transfer is not impaired by previous ovarian cystectomy for ovarian endometrioma.

32 •• Muzii L, Bianchi A, Croce C, *et al.* Laparoscopic excision of ovarian cysts: is the stripping technique a tissue-sparing procedure? Fertil Steril 2002; 77:609–614.

An interesting pathological study that suggests that the stripping technique is atraumatic for the ovary.

33 Hachisuga T, Kawarabayashi T. Histopathological analysis of laparoscopically treated ovarian endometriotic cysts with special reference to loss of follicles. Hum Reprod 2002; 17:432–435.

34 Maneschi F, Marasa L, Incandela S, *et al.* Ovarian cortex surrounding benign neoplasms: a histologic study. Am J Obstet Gynecol 1993; 169:388–393.

35 Koh CH, Janik GM. Laparoscopic microsurgery: current and future status. Curr Opin Obstet Gynecol 1999; 11:401–407.